

# Fixation of Unstable Type II Clavicle Fractures With Distal Clavicle Plate and Suture Button

Peter S. Johnston, MD,\* Benjamin W. Sears, MD,† Mark R. Lazarus, MD,‡ and Barbara G. Frieman, MD,‡

**Summary:** This article reports on a technique to treat unstable type II distal clavicle fractures using fracture-specific plates and coracoclavicular augmentation with a suture button. Six patients with clinically unstable type II distal clavicle fractures underwent treatment using the above technique. All fractures demonstrated radiographic union at 9.6 (8.4–11.6) weeks with a mean follow-up of 15.6 (12.4–22.3) months. American Shoulder and Elbow Surgeons, Penn Shoulder Score, and Single Assessment Numeric Evaluation scores were 97.97 (98.33–100), 96.4 (91–99), and 95 (90–100), respectively. One patient required implant removal. Fracture-specific plating with suture-button augmentation for type II distal clavicle fractures provides reliable rates of union without absolute requirement for implant removal.

**Key Words:** distal clavicle fracture, type II clavicle fractures, open reduction internal fixation

(*J Orthop Trauma* 2014;28:e269–e272)

Distal clavicle fractures account for 10%–30% of all clavicle fractures.<sup>1</sup> Appropriate fracture management, surgical indications, and expected prognosis are intricately related to fracture pattern and stability. Healing complications of distal clavicle fractures are well known with nonunion rates as high as 44% and delayed union in up to 75% of fractures.<sup>1–8</sup> Neer,<sup>3,9</sup> and later Craig,<sup>10</sup> classified distal clavicle fractures into 3 types based on the relationship of the fracture to the coracoclavicular (CC) ligaments and acromioclavicular (AC) joint. Type I and III fractures are, by definition, stable fractures and characteristically managed with nonoperative treatment. Type II fractures involve detachment of the proximal fragment from the CC ligaments and preservation of the AC joint capsule with the distal clavicle maintaining continuity with the scapula. Given the relative instability of type II fractures, surgical management has been proposed as a viable treatment option.<sup>2,3,10,11</sup>

Accepted for publication February 10, 2014.

From the \*Southern Maryland Orthopaedics and Sports Medicine, St. Mary's Hospital, Leonardtown, MD; †Synergy Orthopedics, St. Anthony North Hospital, Westminster, CO; and ‡Thomas Jefferson University Hospitals, Rothman Institute, Philadelphia, PA.

M. R. Lazarus has received consultancy fees and royalties from Tornier, and B. W. Sears is employed with Centura Health System. The other authors report no conflict of interest.

Reprints: Peter S. Johnston, MD, Southern Maryland Orthopaedics and Sports Medicine, 23000 Moakley St, Suite 102, Leonardtown, MD 20650 (e-mail: pjohnston4@hotmail.com).

Copyright © 2014 by Lippincott Williams & Wilkins

Surgical treatment can be challenging given both deforming forces on the proximal clavicle and characteristically small distal fragment that limits quality fixation. Numerous surgical approaches for the management of unstable distal clavicle fractures have been reported, which have yielded varying results, and more notably, diverse rates of associated complications and reoperation.<sup>2,11–26</sup>

We now describe our technique and results for open reduction and internal fixation of displaced type II distal clavicle fractures with fracture-specific plating combined with CC stabilization using a suture button.

## METHODS

### Patient Analysis

Six patients with 6 unstable type II distal clavicle fractures were evaluated from 2010 to 2012. All were men that sustained a traumatic injury including a fall from height, bicycle accident, rugby injury, skiing injury, and motor vehicle collision. No patient was found to have an open fracture and had no other associated injuries. In addition, all patients were found to have a clinically normal neurovascular examination. All demonstrated complete fracture displacement with no cortical contact between the fracture fragments and widening of the CC space. All patients were considered to be at a high risk for potential nonunion. As a result, these patients were believed to be candidates for surgical repair using a novel method of open reduction and internal fixation of the clavicle with suspension of the clavicle to the coracoid using a knotless suture-button anchor system (TightRope; Arthrex, Naples, FL). Postsurgical subjective evaluation was completed using the American Shoulder and Elbow Surgeons (ASES) score, Penn Shoulder score (PSS), and Single Assessment Numeric Evaluation (SANE) score.

### Surgical Procedure

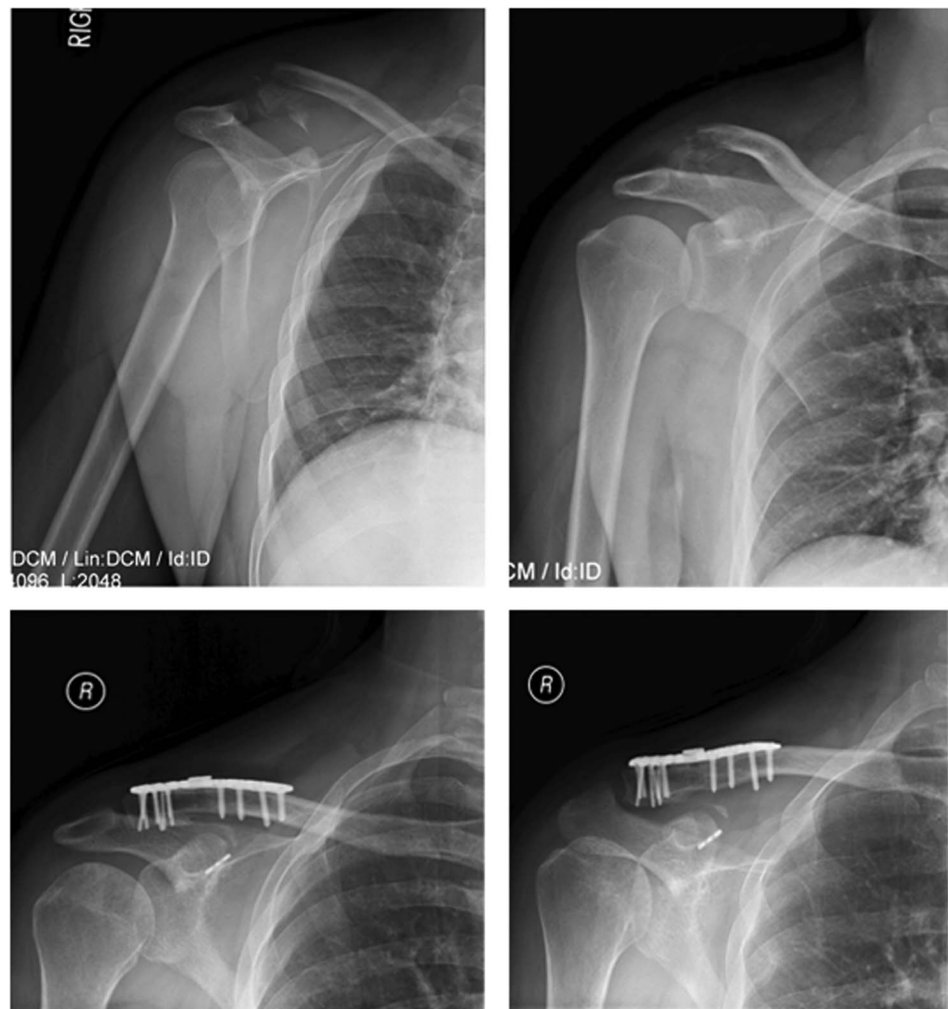After an interscalene peripheral nerve block, patients were placed in a beachchair position, and a 5-cm incision was made longitudinally along the Langer lines extending from the superior portion of the clavicle proximally to the coracoid distally. After skin flaps were mobilized above the level of the fascia, the deltotracheal fascia was incised in line with the axis of the clavicle exposing the fracture. Periosteal stripping of the fracture was minimized, and the AC joint was delineated with a spinal needle to prevent violation of the joint capsule. Exposure was completed by reflecting the anterior deltoid away from the clavicle to allow access to the coracoid base.

The fracture was temporarily reduced with arm elevation and manual pressure on the medial clavicle. When reduced, a fracture-specific distal clavicle plate (Acumed, Hillsboro, OR, or DePuy Synthes, West Chester, PA) was placed in a position that allowed a screw hole to overlie the coracoid for placement of the suture-button device. When the plate was positioned adequately, it was initially secured with a single 3.5-mm bicortical nonlocking screw. The distal fragment was not secured to the plate at this time. Of note, titanium plates were preferred to limit any potential galvanic corrosion with the suture-button device.

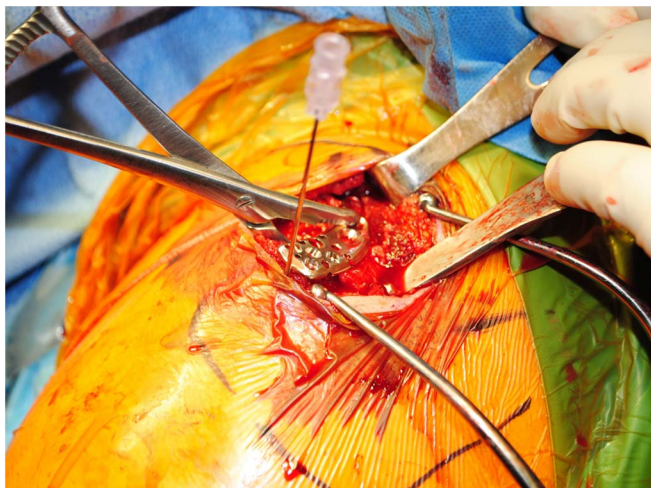
The suture-button device was then placed through the plate to maintain reduction of the medial clavicle to the coracoid and secure distal clavicle fracture fixation. A 2.4-mm drill-tipped guide pin was drilled through the open screw hole in the clavicle plate into the middle of the base of the coracoid, which was exposed with retractors medially and laterally to protect the underlying neurovascular anatomy including the axillary nerve, musculocutaneous nerve, the lateral cord of the brachial plexus, and the axillary artery. A 4-mm cannulated drill was placed over the guide pin, and the clavicle and coracoid were overdrilled. The guide pin was

removed, and a flexible wire was placed through the cannulated slot in the drill to the undersurface of the coracoid. This was retrieved with a right angle clamp and used to shuttle traction sutures attached to the oblong button through the drill holes superiorly to the undersurface of the coracoid. After the button was passed through the bone tunnels, it was secured at the base of the coracoid by flipping the traction sutures.

After the knotless anchor system was adequately positioned, the clavicle was rereduced to the distal fragment with upper extremity elevation and caudal force on the medial clavicle. With the fracture reduced, the suture device's accompanying round button was advanced to the superior aspect of the plate. Fluoroscopic imaging was then used to verify reduction. The suture was then tied securely with 5 alternating half hitches to the top of the plate. The fracture reduction was obtained and held with reduction forceps, and the reduced distal fracture fragment was secured to the plate by placement of remaining distal locking screws. The remaining medial holes were filled with cortical screws as needed. After fluoroscopic confirmation of the reduction was obtained, the deltotracheal fascia was repaired with absorbable sutures and skin closed with a running subcutaneous suture and steri-strips.



**FIGURE 1.** Preoperative and postoperative radiographs of a 28-year-old male patient with an acute type II distal clavicle fracture treated with our technique. The postoperative radiographs demonstrate fracture healing and maintenance of anatomic reduction at 12 weeks after surgery.

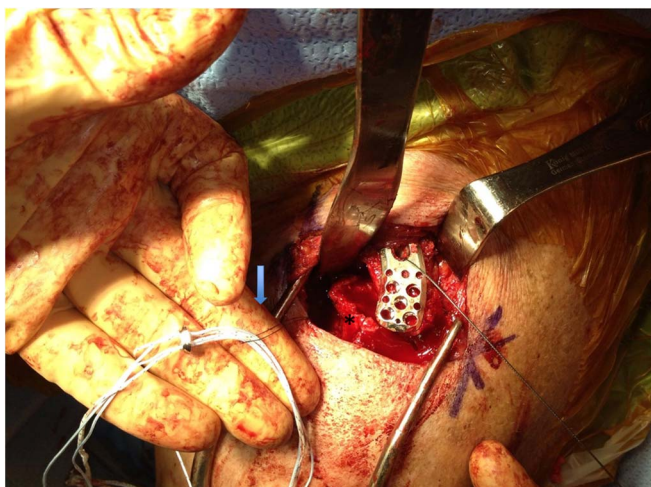


**FIGURE 2.** Temporary reduction of the distal clavicle plate to the medial clavicle before fixation. Spinal needle delineates AC joint.

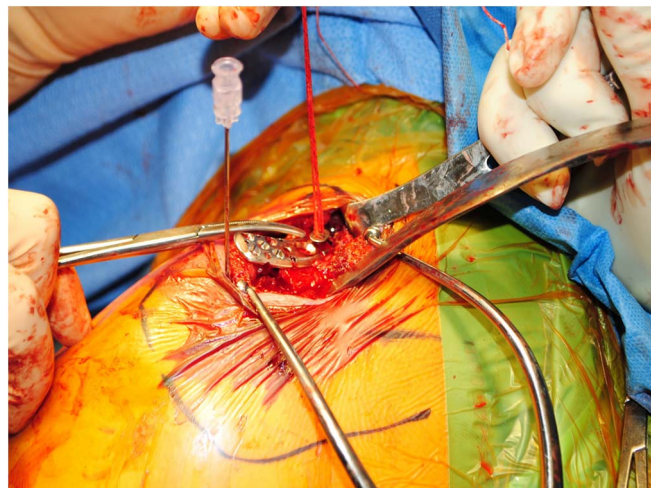
Postoperatively, patients were kept in a sling for 6 weeks, and not permitted active use of the arm. Passive range of motion exercises consisting of forward flexion and external rotation were initiated at 2 weeks. At 6 weeks, the sling was discontinued but a 5 lb weightlifting restriction was enforced until 12 weeks after surgery. At that time, use of the arm was advanced based on radiographic healing of the fracture (Figs. 1–5).

### RESULTS

All patients were found to achieve radiographic union at a mean of 9.6 (8.4–11.6) weeks from injury. Outcome measures including ASES, SANE, and PSS scores were obtained for all patients after clinical discharge through phone interview at a mean of 15.6 (12.4–22.3) months. The mean



**FIGURE 3.** The flexible wire before the passage of suture-button construct (arrow) through the coracoid and the clavicle. \*Distal clavicle.

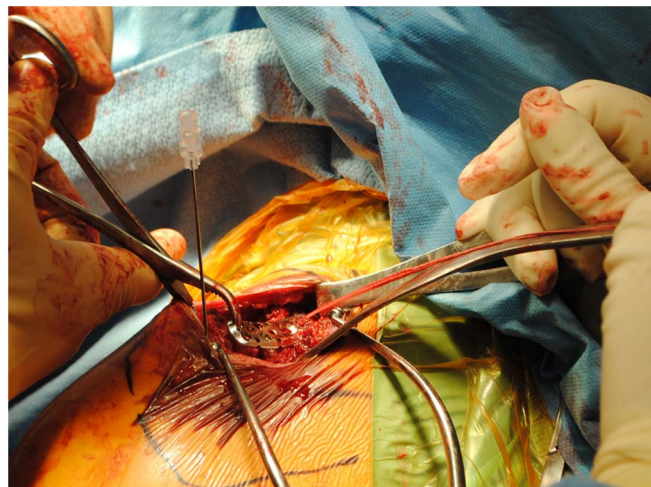


**FIGURE 4.** The suture button reduced to plate to assist with fracture reduction and vertical stability.

ASES score for this series was 97.97 (98.33–100). The mean PSS for this series was 96.4 (91–99).

Patient perception of shoulder normalcy and functionality were found to be excellent. The mean SANE score for this series was 96 (90–100). The patient-reported functionality of the affected shoulder included a mean score of 9.6 (8–10) (Fig. 5). Additionally, in all patients, their perception of the range of motion was full.

No patients were found to have any intraoperative or perioperative complications. One patient required the removal of the plate and tightrope construct for a painful implant with no postoperative sequelae. Two other patients reported mild clinical complaints with the implant, but these were not severe enough to require removal. Outcome measures found that 50% (3 of 6) of patients reported “some difficulty” with sleeping, however, all patients returned to their previous occupation at full duty with no difficulty.



**FIGURE 5.** Reduction forceps for the final fracture reduction before distal screw placement.

## DISCUSSION

Displaced type II distal clavicle fractures are frequently unstable and, by definition, have detachment of the conoid and trapezoid ligaments leading to a cephalad deforming force on the proximal fragment. Given their inherent instability, type II distal clavicle fractures are frequently treated with operative means.<sup>2,3,10,11</sup>

A review of the literature for surgical approaches to type II distal clavicle fractures provides readers with numerous techniques for surgical fixation including transacromial wire fixation, the use of a tension band, screw fixation, transfer of the coracoacromial ligament to the distal clavicle, hook plating, and arthroscopic fixation.<sup>2,11-26</sup> Challenges with surgical management include fracture comminution, a characteristically small distal fragment-limiting fixation, and significant deforming forces. The subcutaneous location often requires implant removal secondary to prominence. Additionally, other described fixation methods, which cross the AC joint, require removal given the dynamic relationships essential to normal shoulder motion. Our technique addresses these challenges with the use of a fracture-specific plate augmented with nonrigid CC fixation. Additionally, this construct allows for bridging of comminution if needed and adjustable tensioning of the CC ligament reconstruction for assistance with distal fracture reduction.

All of our patients went on to union at an average of 9.6 weeks with outcomes comparable with other reported techniques with more than 1 year of follow-up. Reoperation for implant removal was required in one of the patients in our series because of prominent sutures from the knot, which were symptomatic when carrying a shoulder bag. After the implants were removed, the patient was free of symptoms and satisfied reporting a SANE score of 95. This is in contrast to other techniques that ultimately require the removal of CC screws or AC hook plates.

The development of both fracture-specific clavicle plates and suture buttons, which allow dynamic fixation through the plate, without the fear of clavicular “sawing” by the sutures, has provided the surgeon with unique options for the management of these difficult fractures. Additionally, there seems to be no absolute requirement for implant removal.

## REFERENCES

- Robinson CM, Cairns DA. Primary nonoperative treatment of displaced lateral fractures of the clavicle. *J Bone Joint Surg Am.* 2004;86:778–782.
- Neer CS II. Fracture of the distal clavicle with detachment of the coracoclavicular ligaments in adults. *J Trauma.* 1963;3:99–110.
- Neer CS II. Fractures of the distal third of the clavicle. *Clin Orthop Relat Res.* 1968;58:43–50.
- Robinson CM, Court-Brown CM, McQueen MM, et al. Estimating the risk of nonunion following nonoperative treatment of a clavicular fracture. *J Bone Joint Surg Am.* 2004;86:1359–1365.
- Nordqvist A, Petersson C, Redlund-Johnell I. The natural course of lateral clavicle fracture: 15 (11-21) year follow-up of 110 cases. *Acta Orthop Scand.* 1993;64:87–91.
- Deafenbaugh MK, Dugdale TW, Staeheli JW, et al. Nonoperative treatment of Neer type II distal clavicle fractures: a prospective study. *Contemp Orthop.* 1990;20:405–413.
- Edwards DJ, Kavanagh TG, Flannery MC. Fractures of the distal clavicle: a case for fixation. *Injury.* 1992;23:44–46.
- Rokito AS, Zuckerman JD, Shaari JM, et al. A comparison of nonoperative and operative treatment of type II distal clavicle fractures. *Bull Hosp Jt Dis.* 2002–2003;61:32–39.
- Neer C II. Fractures and dislocations of the shoulder. In: Rockwood CA Jr, Green DP, eds. *Fractures in Adults.* Philadelphia, PA: JB Lippincott; 1984;711–712.
- Craig EV. Fractures of the clavicle. In: Rockwood CA, Green DP, eds. *Fractures in adults.* 6th ed. Vol 1. Philadelphia, PA: Lippincott Williams & Wilkins; 2006:1216–1217.
- Herrmann S, Schmidmaier G, Greiner S. Stabilisation of vertical unstable distal clavicular fractures (Neer 2b) using locking T-plates and suture anchors. *Injury.* 2009;40:236–239.
- Webber MC, Haines JF. The treatment of lateral clavicle fractures. *Injury.* 2000;31:175–179.
- Wang SJ, Wong CS. Extra-articular knowles pin fixation for unstable distal clavicle fractures. *J Trauma.* 2008;64:1522–1527.
- Bezer M, Aydin N, Guven O. The treatment of distal clavicle fractures with coracoclavicular ligament disruption: a report of 10 cases. *J Orthop Trauma.* 2005;19:524–528.
- Chen CH, Chen WJ, Shih CH. Surgical treatment for distal clavicle fracture with coracoclavicular ligament disruption. *J Trauma.* 2002;52:72–78.
- Goldberg JA, Bruce WJ, Sonnabend DH, et al. Type 2 fractures of the distal clavicle: a new surgical technique. *J Shoulder Elbow Surg.* 1997;6:380–382.
- Anderson K. Evaluation and treatment of distal clavicle fractures. *Clin Sports Med.* 2003;22:319–326, vii.
- Heim U, Pfeiffer KM. *Internal Fixation of Small Fractures: Technique Recommended by the AO-ASIF Group.* 3rd ed. New York, NY: Springer-Verlag; 1987.
- Kalamaras M, Cutbush K, Robinson M. A method for internal fixation of unstable distal clavicle fractures: early observations using a new technique. *J Shoulder Elbow Surg.* 2008;17:60–62.
- Kashii M, Inui H, Yamamoto K. Surgical treatment of distal clavicle fractures using the clavicular hook plate. *Clin Orthop Relat Res.* 2006;447:158–164.
- Tambe AD, Motkur P, Qamar A, et al. Fractures of the distal third of the clavicle treated by hook plating. *Int Orthop.* 2006;30:7–10.
- Checchia SL, Doneux PS, Miyazaki AN, et al. Treatment of distal clavicle fractures using an arthroscopic technique. *J Shoulder Elbow Surg.* 2008;17:395–398.
- Banerjee R, Waterman B, Padalecki J, et al. Management of distal clavicle fractures. *J Am Acad Orthop Surg.* 2011;19:392–401.
- Eskola A, Vainionpää S, Päätiälä H, et al. Outcome of operative treatment in fresh lateral clavicular fracture. *Ann Chir Gynaecol.* 1987;76:167–169.
- Fazal MA, Saksena J, Haddad FS. Temporary coracoclavicular screw fixation for displaced distal clavicle fractures. *J Orthop Surg (Hong Kong).* 2007;15:9–11.
- Nourissat G, Kakuda C, Dumontier C, et al. Arthroscopic stabilization of Neer type 2 fracture of the distal part of the clavicle. *Arthroscopy.* 2007;23:674.e1–674.4.