

# A patient's guide to: Arthroscopy of the Hip

Brian J. White MD

Assistant Team Physician Denver Nuggets  
Western Orthopaedics - Denver, Colorado



# Introduction

- This is designed to provide you with a better understanding of:
  - Anatomy of the Hip
  - Biomechanics of the Hip joint
  - The rationale behind Hip Arthroscopy
  - Expectations of the procedure



# Disclosures

- I am a Consultant for Smith and Nephew Hip Arthroscopy in two ways:
  - Education
    - I teach Orthopaedic Surgeons across the country how to safely access the Hip arthroscopically and treat FAI and Repair Labral Tears
  - New Product development
    - I help design instrumentation to improve both the safety and technique of Hip arthroscopy



# My Training

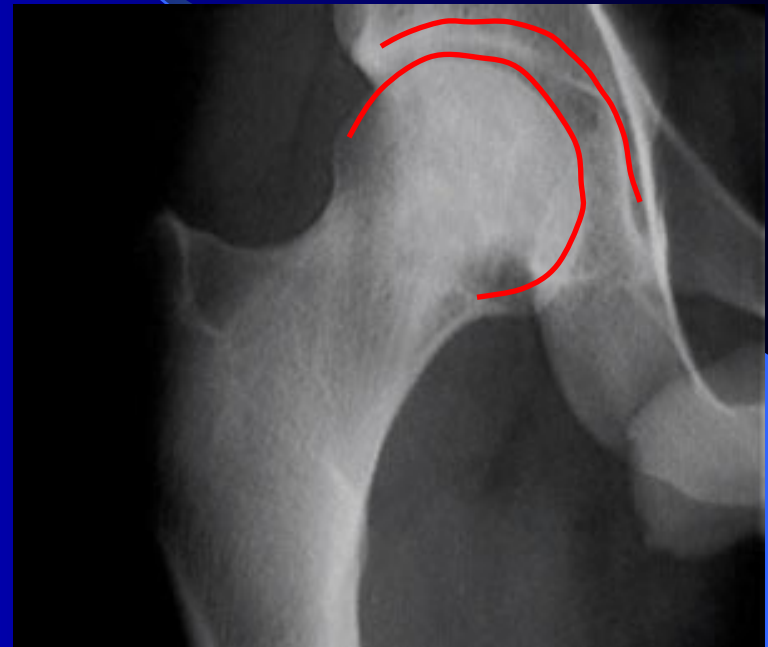- Washington and Lee University
  - BA Chemistry
- Georgetown University School of Medicine
  - Medical Degree
- NYU/Hospital for Joint Diseases
  - Orthopaedic Surgical Residency
- Steadman-Hawkins Sports Medicine, Vail, CO
  - Sports Medicine Fellowship in Knee, Shoulder and Hip
  - Mentors: Dr. Steadman and Dr. Philippon

# Femoracetabular Impingement (FAI) and Labral Tears

- On average, Patients with this Problem see 4 physicians and wait 2 years before the appropriate diagnosis is made.

# Anatomy

- The hip is a ball and socket joint formed by two bony structures
  - The Femoral Head or Ball
  - The Acetabulum or Cup



# What is FemorAcetabular Impingement (FAI)?

- The Ball and Cup are not perfectly shaped for each other.
- With normal rotation of the imperfectly shaped hip joint, there is an abnormal contact between the two sides of the joint.
- This is the impingement which can lead to tearing of the labrum and/or cartilage.
- Impingement itself is not painful – the pain comes from the labral tear

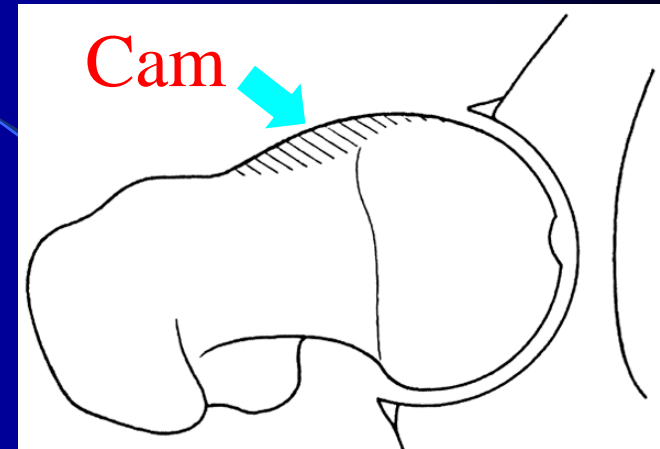
# There are Two types of FAI

- CAM type:

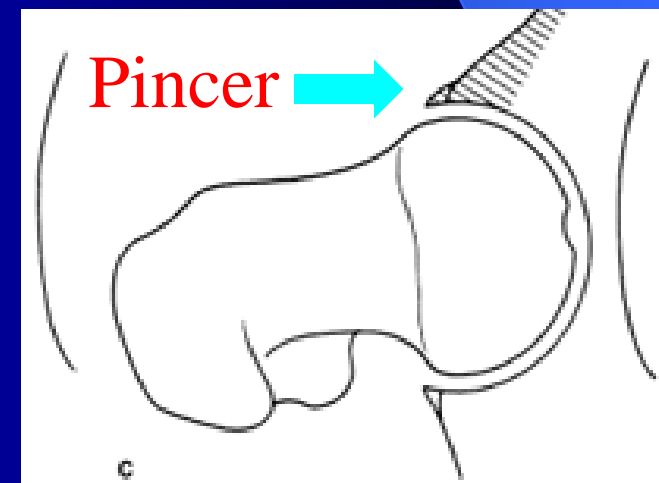
- Ball is oval shaped rather than round
- With Hip rotation it does not fit fully into the round Cup

- PINCER type:

- The Cup over covers the Ball
- This prevents the Ball from fitting properly into the Cup

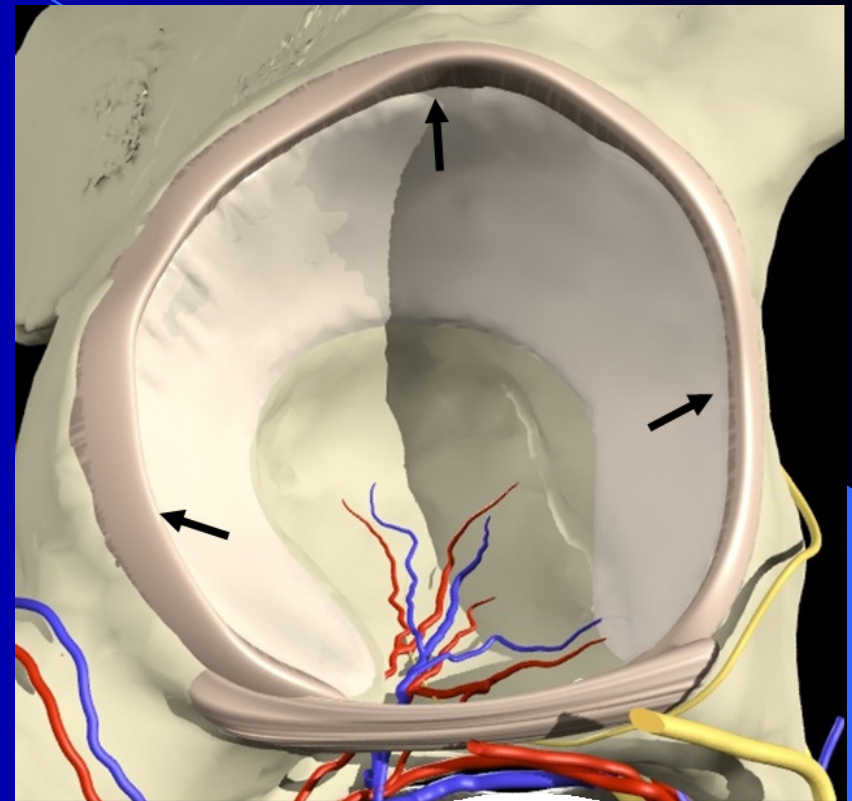


Shaded areas represent the bone that shouldn't be there



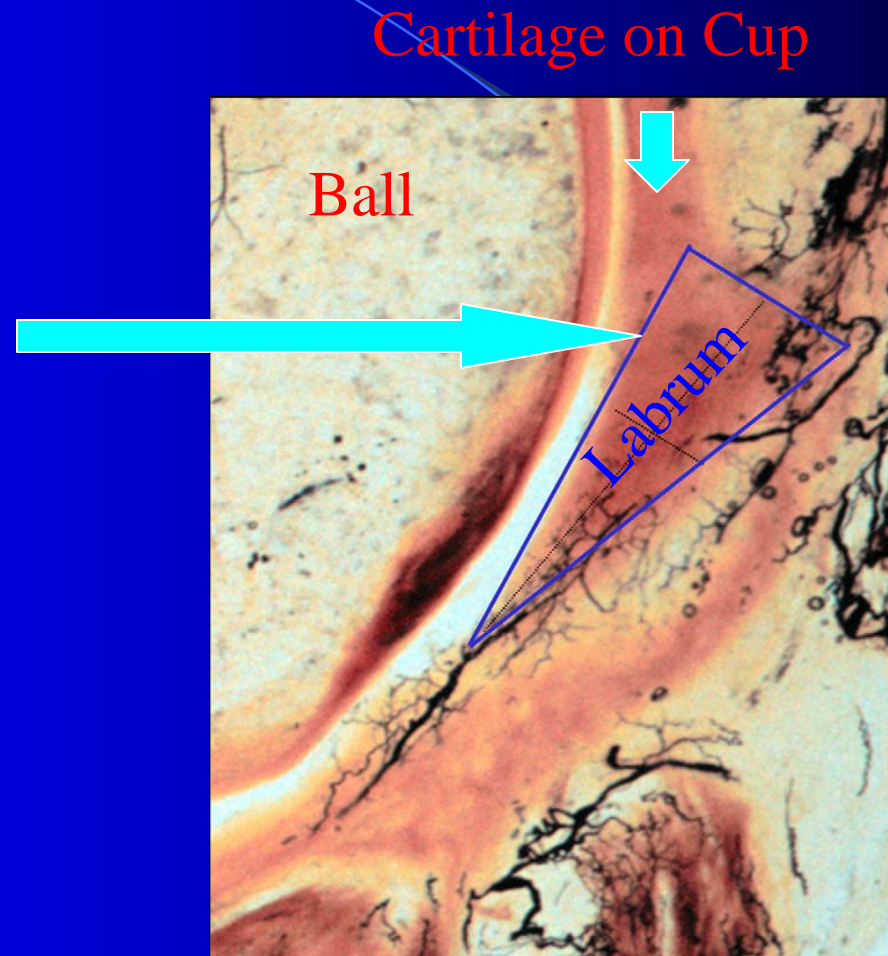
# Acetabular Labrum

- The Labrum is a soft tissue extension off of the Cup
- It can tear because of underlying FAI
- When it is torn it can be quite painful
- Function of Labrum:
  - Forms a seal with the Ball to contain joint fluid
    - Similar to a washer on a facet
  - Contributes to stability of the Hip
  - Protects Cartilage of the Cup

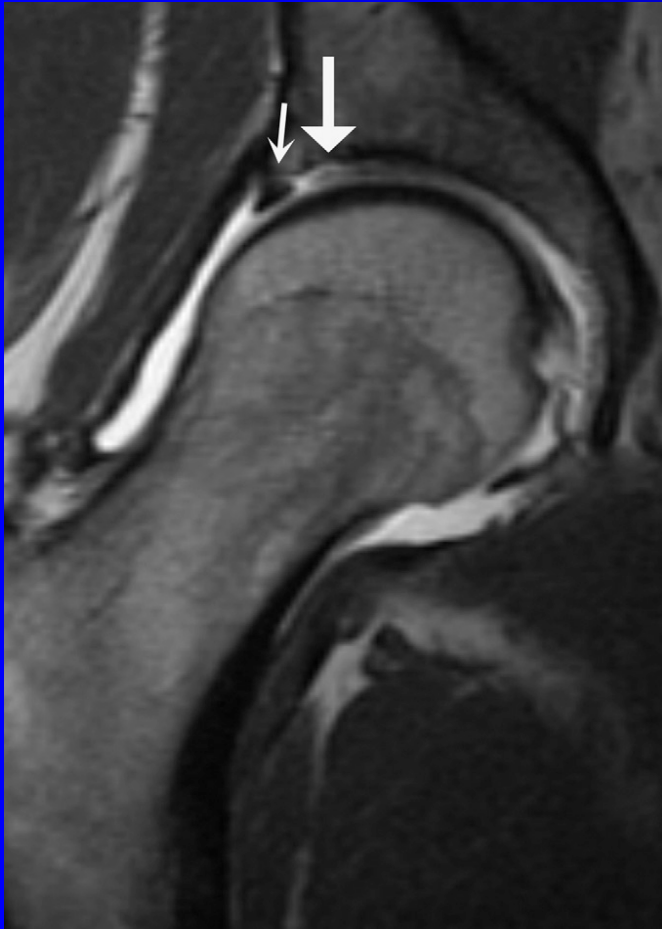


# Labral Cross Section

The Cartilage and the labrum run together. This means that when the labrum is torn often the cartilage is damaged as well. This injury can be the beginning of Arthritis of the Hip.

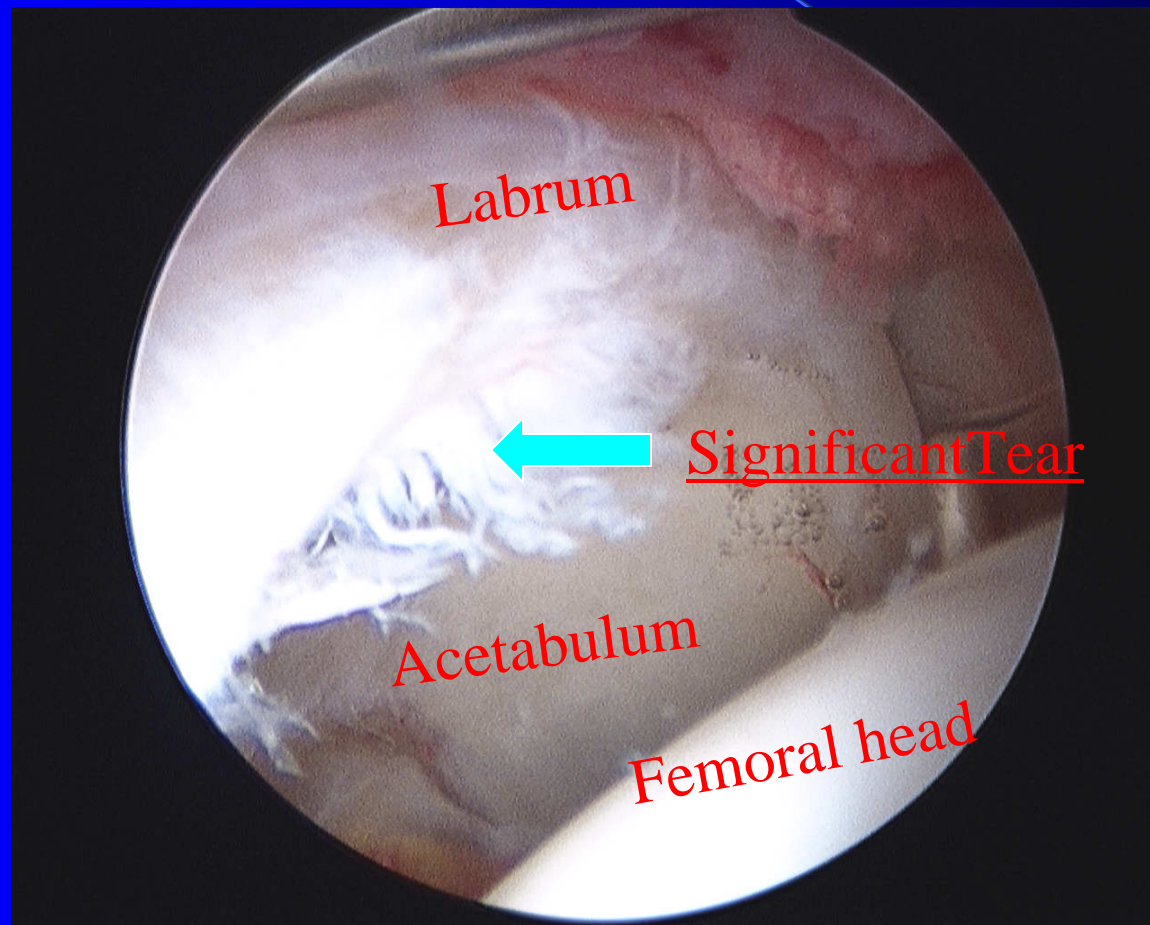


# MRI with Arthrogram



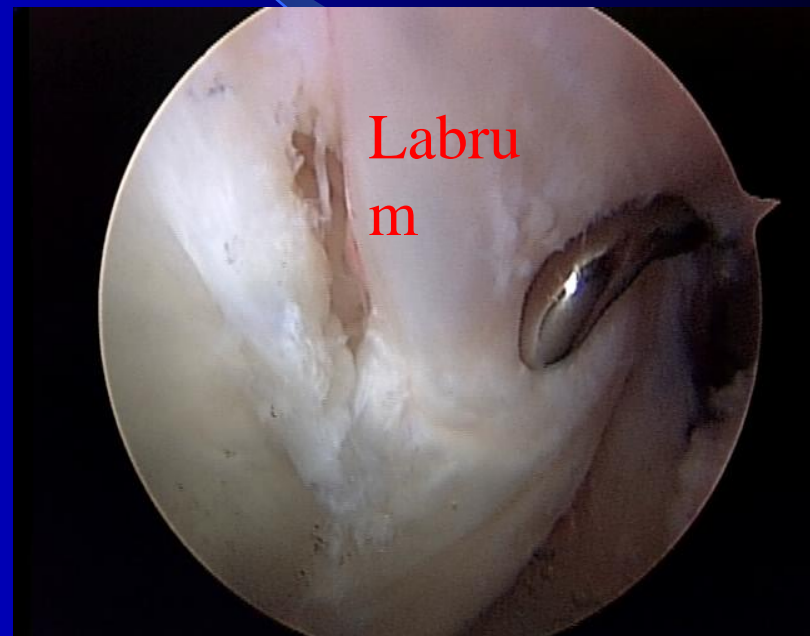
- MRI done with an injection is the best type of imaging that we have now.
- However, it is NOT perfect and does miss some labral tears
- Arthroscopy is the **Gold Standard** for diagnosing Labral Tears

# Read as a "Normal" MRI



# Acetabular Labral Tears

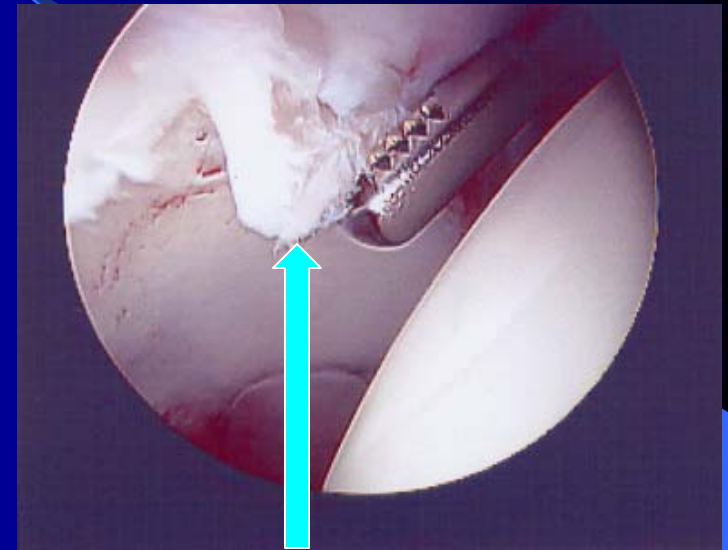
- Most tears are from minor or subtle injuries
- 90% occur in conjunction with FAI
- Symptoms: groin pain worsened with use, pivoting or long sitting
- Occasionally clicking or catching



**WESTERN  
ORTHOPAEDICS**

# The Problem with CAM FAI

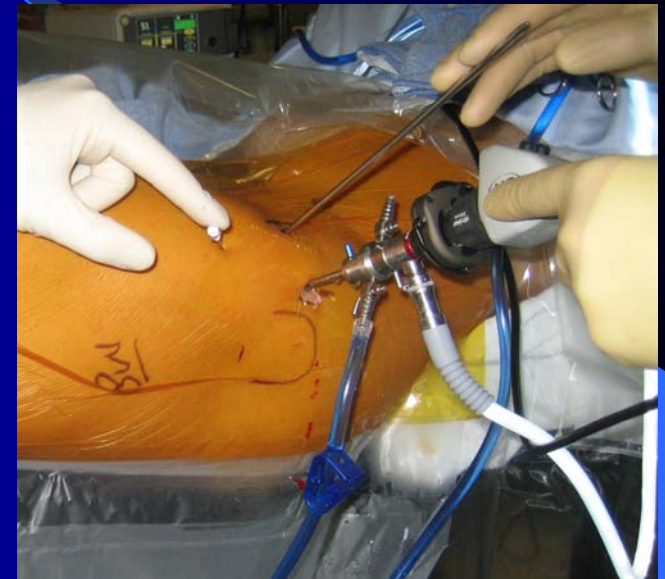
- CAM type of FAI can injure the cartilage when it tears the labrum
- Sometimes, the cartilage of the Cup can peel off of the bone. If present:
  - The cartilage can not be re-attached
  - May require a Microfracture procedure to try and make new cartilage



Cartilage peeling off of cup

# Hip Arthroscopy

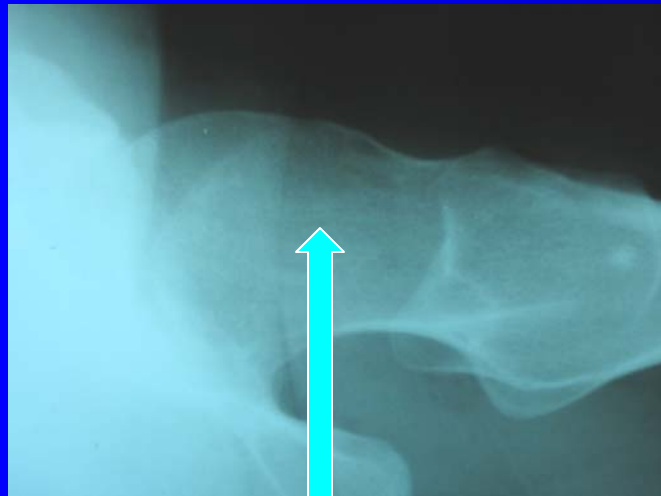
- Basic Arthroscopic procedures for the hip were first described for the hip in the 1970's
- But the evolution of this surgery has been slow because:
  - The Hip is deep within the body and is difficult to get to (unlike the shoulder and the knee)
  - Poor understanding of problems that can occur with the Hip joint
  - We lacked the appropriate instruments to safely operate on the Hip Arthroscopically



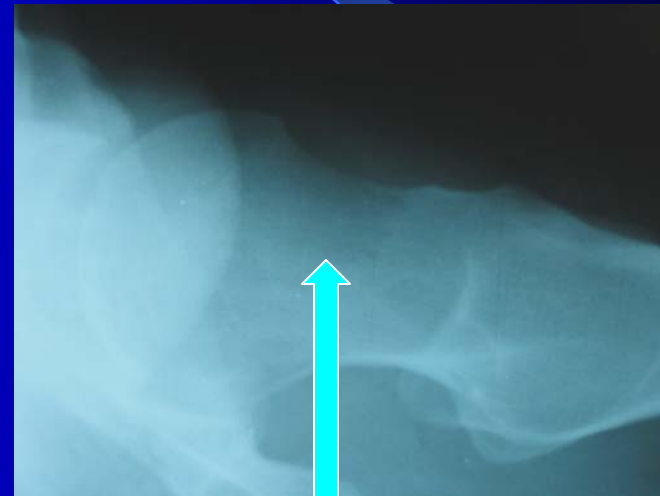
# Hip Arthroscopy Now

- Hip Arthroscopy has evolved significantly in the last several years to treat Labral tears and FAI.
  - CAM- the Ball can be reshaped to make it round
  - Pincer- the Cup can be trimmed back to treat the overcoverage.
  - Labral Tear- Suture anchors can repair Labrum
  - Cartilage Injury:
    - Can be shaved to stabilize the loose cartilage
    - Microfracture procedure can be done to regenerate cartilage

# Reshaping the ball to make it Round - Femoral Osteoplasty

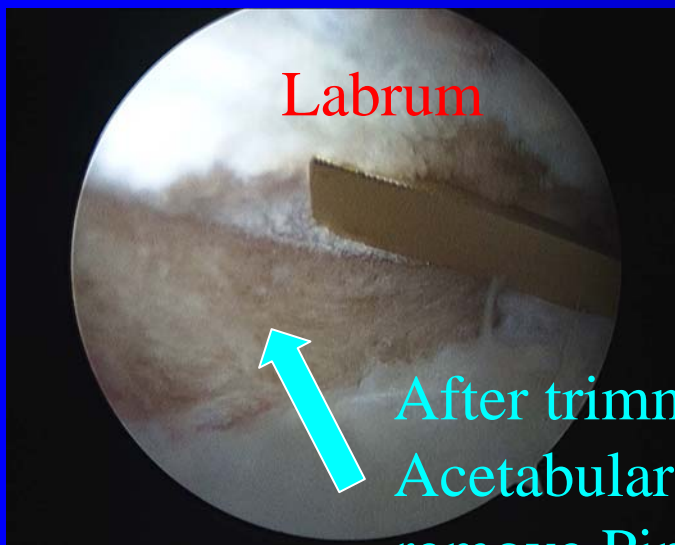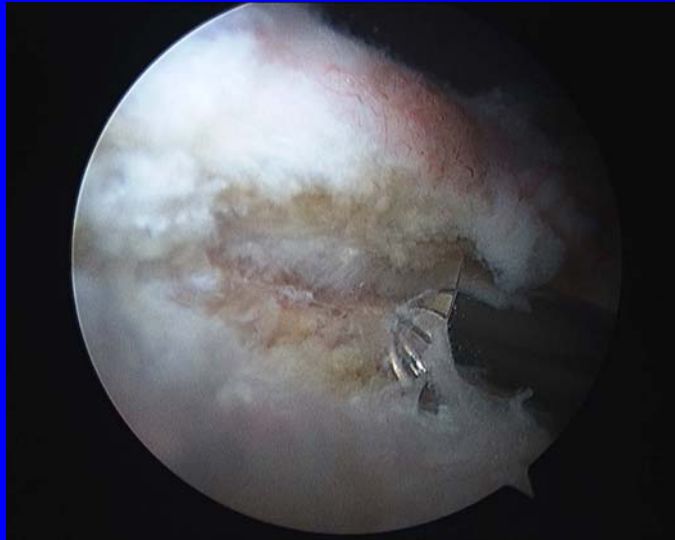


Before surgery-note  
oval shape



After surgery-bone  
removed to make it round.  
Now it will fit better into  
the cup

# Trimming the Cup – Acetabular Rim Trimming



Labrum

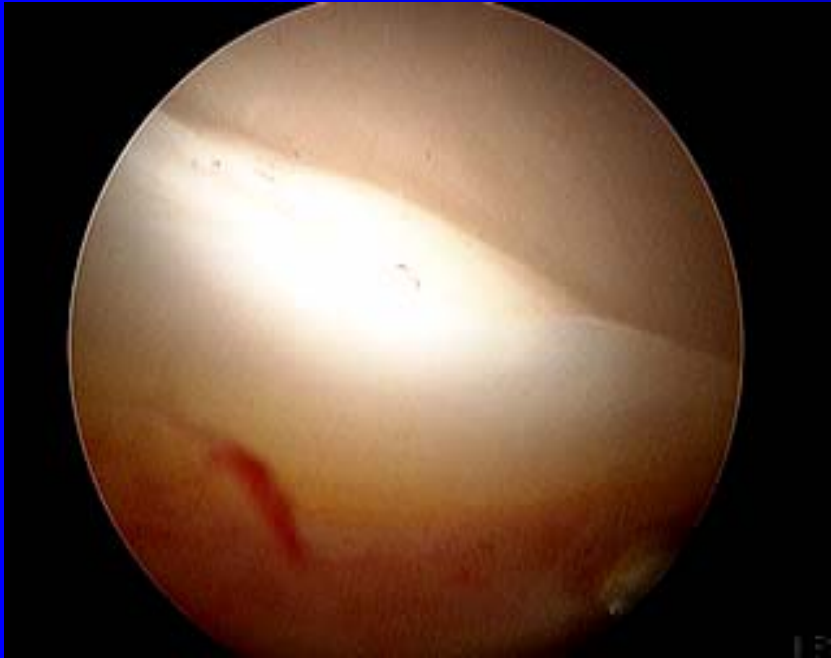After trimming  
Acetabular Rim to  
remove Pincer

- Important for both the Labral Repair as well as removing the Pincer
- I keep the normal attachment between the cartilage and Labrum intact for this step when possible

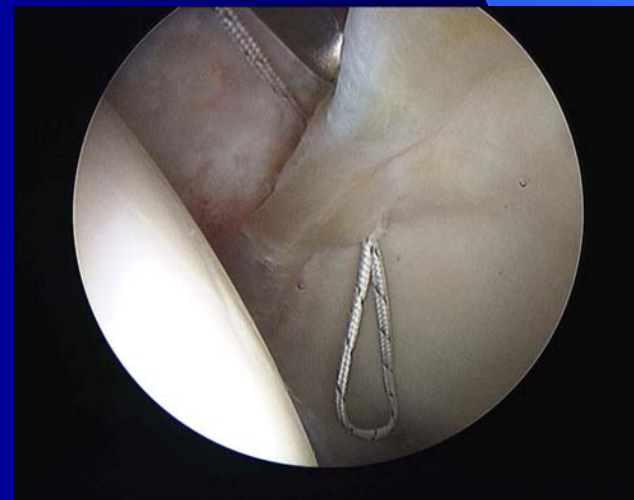

# Positive Wave Sign

- Labrum is hypermobile and it causes early separation of the cartilage from the Cup
- MRI is often Normal
- Diagnostic injection is sometimes used to confirm diagnosis

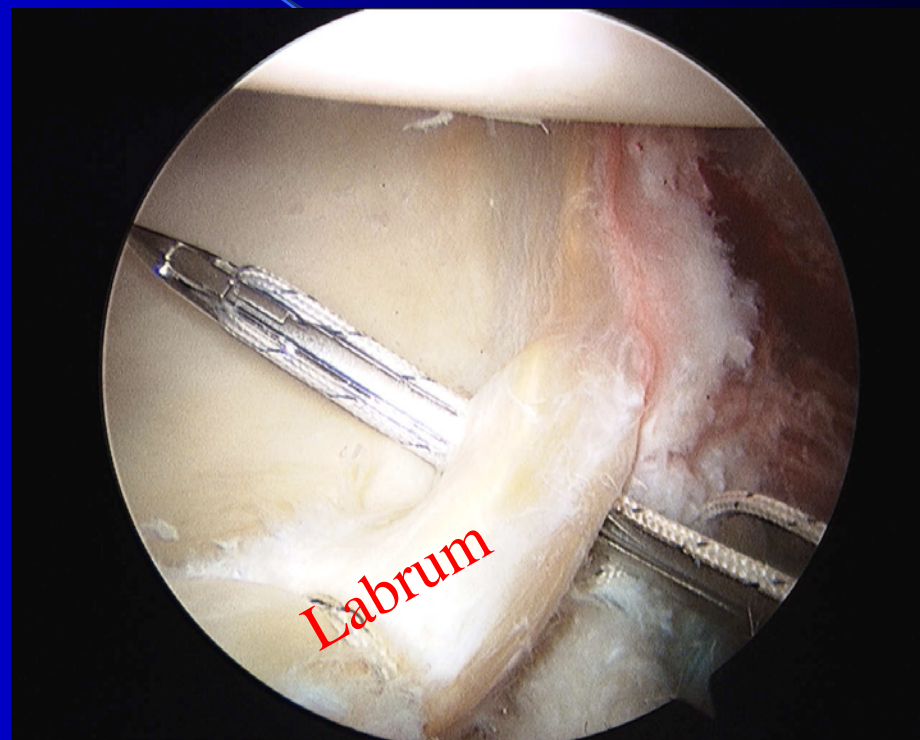


I repair this with sutures to reattach both the labrum and cartilage



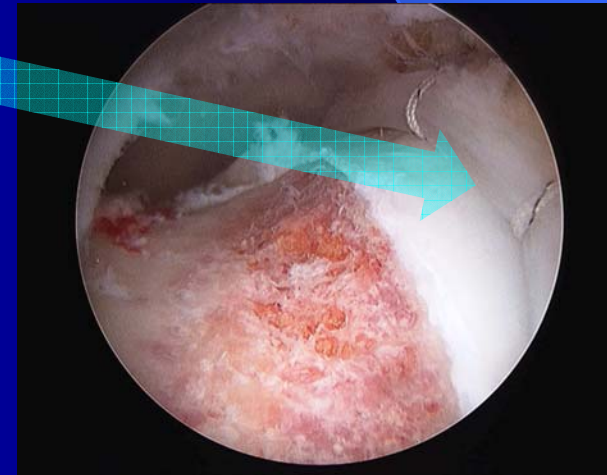
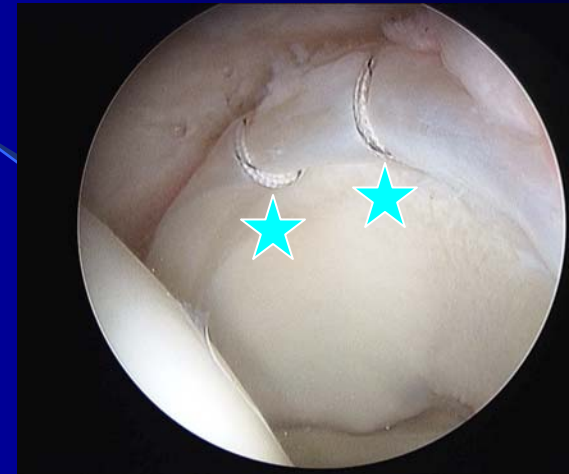# Labral Repair

- Suture is passed around the labrum to secure it back to the edge of the Cup

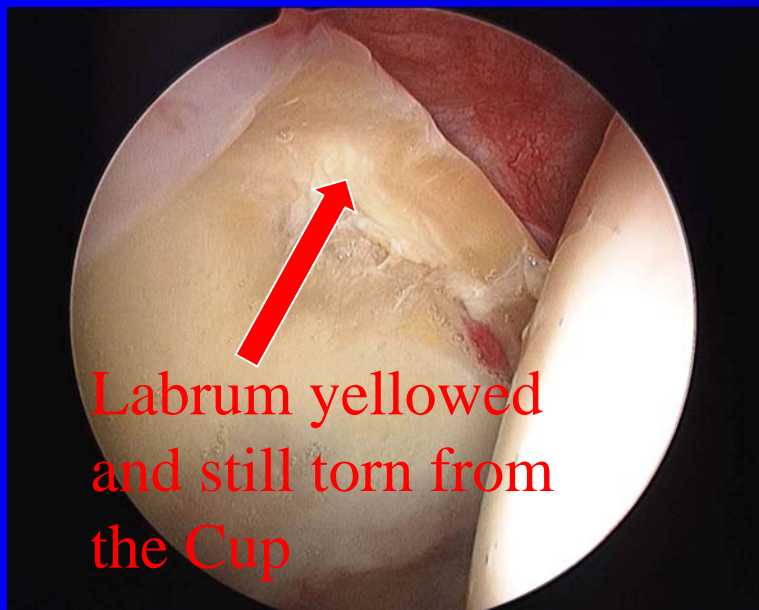

# Labral Repair

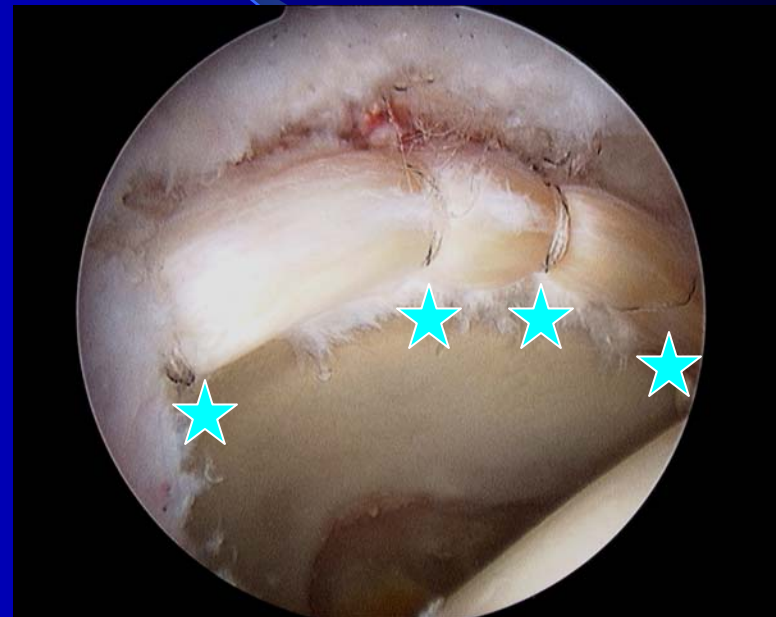2 anchor labral repair  
showing anatomic refixation  
of labrum and excellent seal  
of the labrum with the  
femoral head



# I do not believe in Labral Debridement.

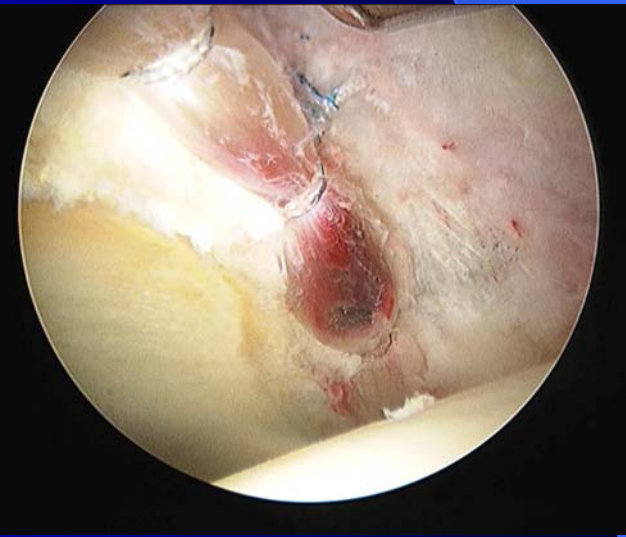

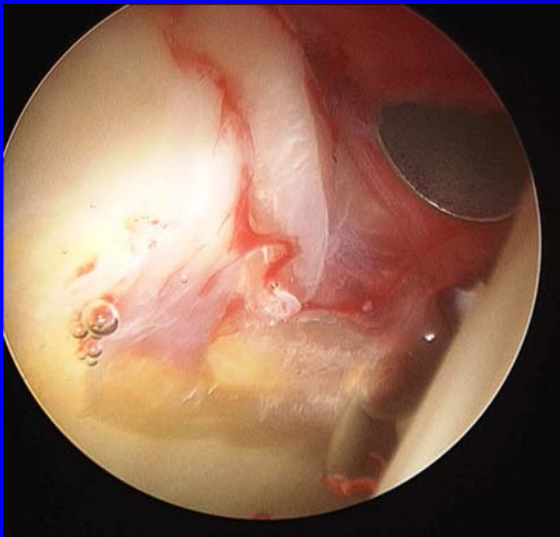
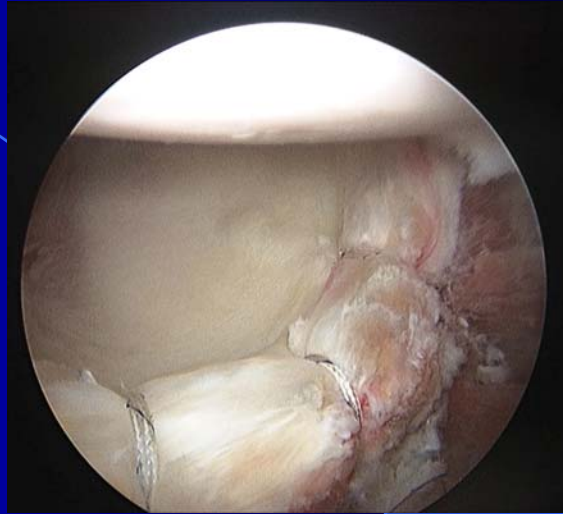

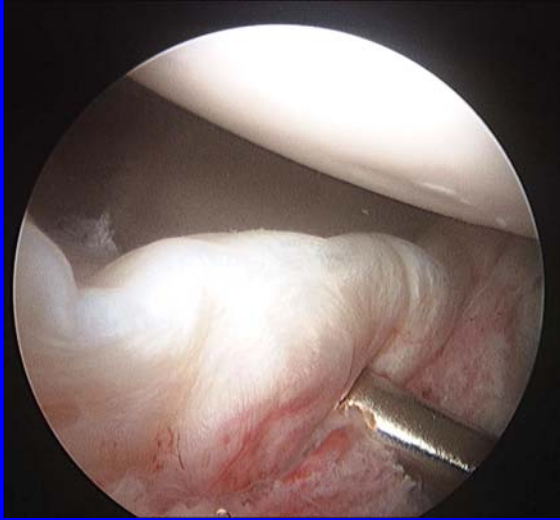


Previous thermal labral debridement done by another physician that failed



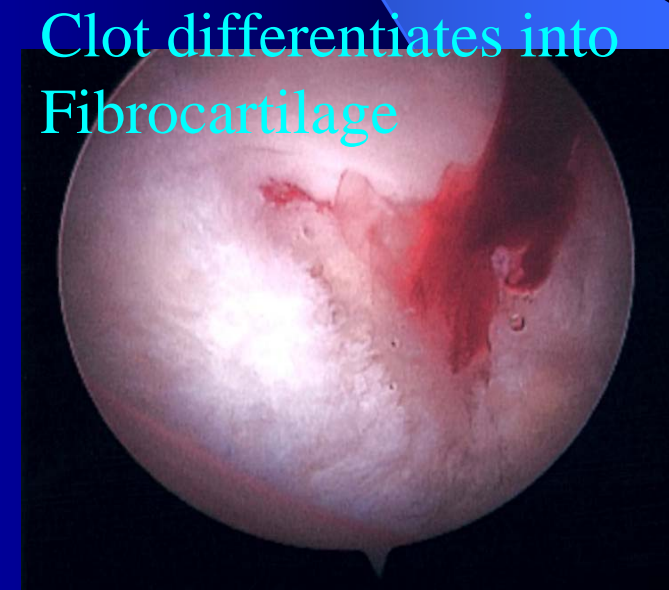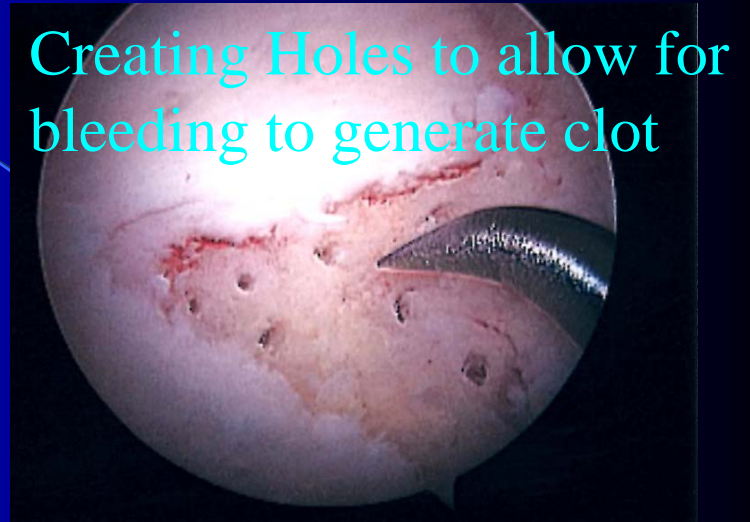Revision Arthroscopy performed by me with repair of labrum. Patient has now fully recovered and is pain free

# I Repair Degenerative Labral Tears



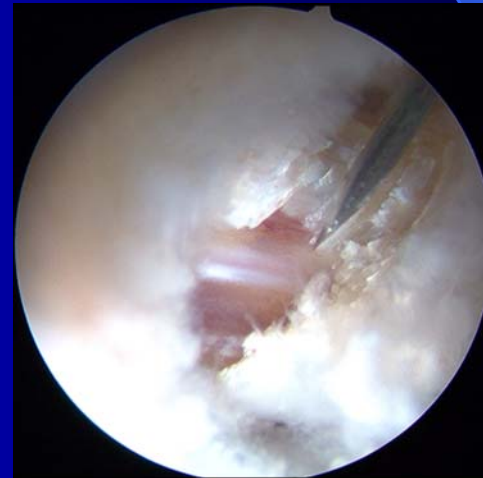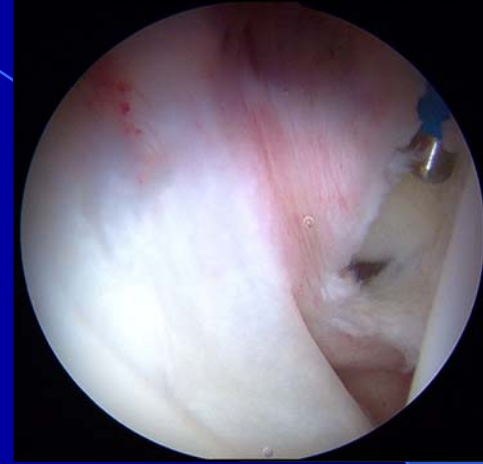# Microfracture Procedure

- Performed when cartilage has peeled off of the cup
- Generates a type of cartilage to fill the defect
  - This is similar to repairing a pothole on a road
- The Rehabilitation for this is different:
  - 6 wks of crutches (rather than 3)
  - 6 wks of using the CPM or bending machine for 6-8 hrs per day (rather than 3 wks)
  - This protects the clot and shapes it properly



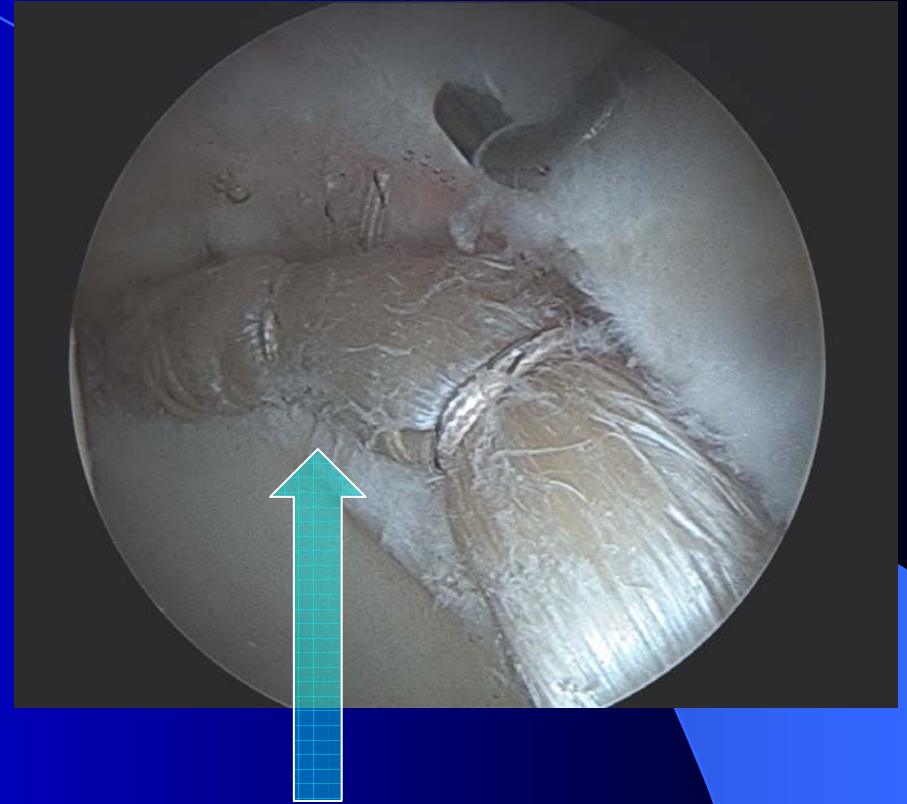
# Iliopsoas Tendon Release

- For patients who have painful, audible popping that occurs several times per day
- Tendon is lengthened arthroscopically to loosen it so that doesn't have enough tension to pop
- No patients have had postoperative weakness



# Labral Reconstruction

- I can make a New labrum from Cadaver Graft.
- Everything is done arthroscopically.
- Performed when:
  - A previous surgery removed a significant portion of the patient's labrum
  - Labrum is severely degenerative and can not be repaired



NEW labrum made from IT band  
Cadaver Graft

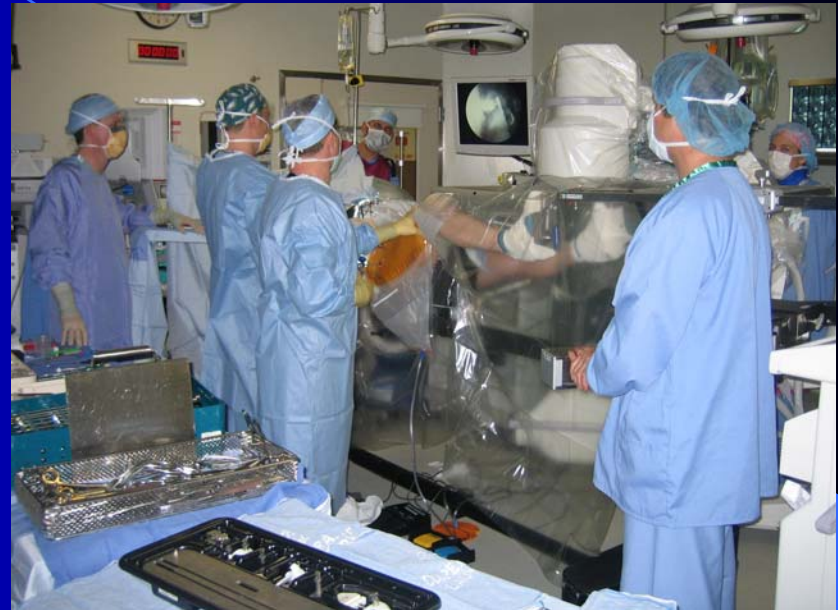\* IT band is soft tissue on the side of the thigh

# Conclusions from Literature

- Hip arthroscopy can significantly improve patient's symptoms and function
- Labral Repair works better than removing or debriding the torn Labrum
- Must treat the FAI, not just the labrum. You have to treat the problem which caused the labrum to tear.
- Arthroscopic patients recover faster and do better than Open Hip Dislocation Procedures
- Uncertain if the natural progression of arthritis is affected, but surgery is probably helpful if the labral tear is repaired early

# What to Expect

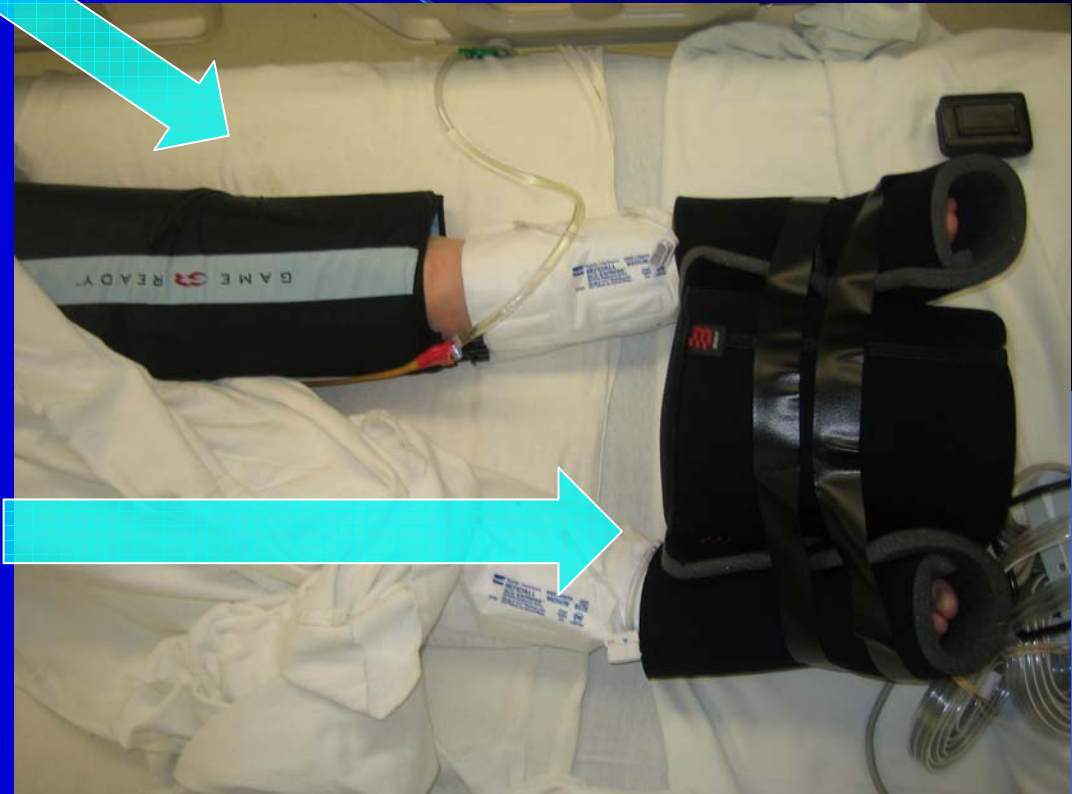
- Overnight Stay in Hospital
  - All surgeries are performed at Presbyterian St Luke's Hospital
- I use both a Spinal or Epidural combined with General Anaesthesia
- Catheter is placed in your bladder while you are asleep
- Physical Therapy
  - Initiated 3-5 days after surgery
  - Our office will help you choose your therapist if you were not referred by one to me



**WESTERN  
ORTHOPAEDICS**

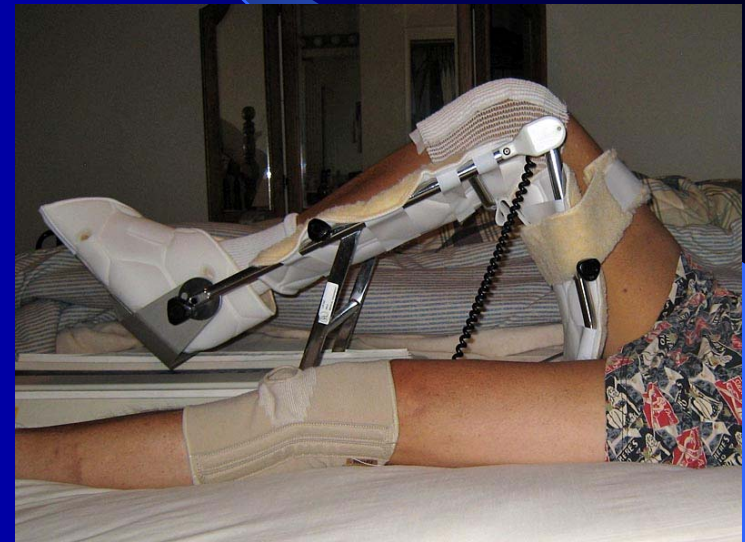# After Surgery

- Game Ready- an icing machine which is used to reduce swelling for about 2 weeks
- Bledsoe Positioning Kit-worn to keep the feet facing forward and to prevent external rotation (used at night for 2 weeks)



# CPM or Bending Machine

- Slowly moves the hip after surgery to prevent scar tissue
- Used for 4-6 hours per day for 3 wks
- If a microfracture procedure was performed: 6-8 hrs/day for 6 wks
- Should not exceed 70 degrees of Flexion
- Can be worn at night



# Driving?

- In general, I recommend waiting until you feel safe to begin driving again. Some general guidelines are:
  - Right sided surgery usually takes a little longer to return safely
  - I recommend waiting until you are almost off crutches and off narcotic pain medications
  - Usually this takes roughly 3-4 weeks

# Return to Work?

- For the most part this is determined by the nature of your job
  - For desk or sedentary work: 2-4 weeks
  - Manual/Heavy work: 4-6 months
  - School: 1-2 weeks
- Our office will assist with any paperwork necessary for your employer

# Rehabilitation

- Crutches for 3 wks with partial weightbearing (6 wks if microfx performed)
- Foot stays straight up or forward for 2 wks to protect from a dislocation (Poss. longer in certain pts.)
- \*\*\*\*Slow with Hip Flexors\*\*\*\*

**Hip Flexor Tendinitis** is a devastating, preventable complication with no cure and is the result of **inappropriate activity by you** during your recovery.
- Return to full sport is about 6 mos.

# How do Patient's do?

- I perform 6-9 Hip Arthroscopies per week
- My Database of all patients since July 2009 shows:
  - Patients are highly satisfied with their procedure
    - They rate their level of satisfaction as a 9-10 out of 10
  - Hip Score – Patients assess their pain and function on this 100 point scale (100 points represents perfect, painless function)
    - Patients significantly improve with the surgery. On average, they gain 25-35 points on this scale.
  - Pain score-10 point pain scale (10 is the worst)
    - Before Surgery: pain is rated as 5-7 at its worst
    - After Surgery: no pain to 2 at its worst

# Thank you

- I hope this has allowed you to better understand your diagnosis and what hip arthroscopy can offer you for your condition.

